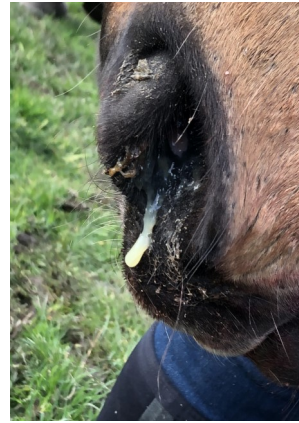
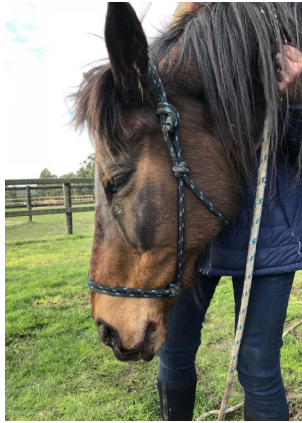
## Case of the Month - December 2018

### Chance - Tooth root infection with associated 2° sinus infection



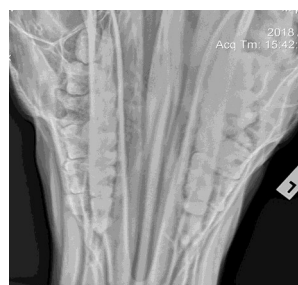
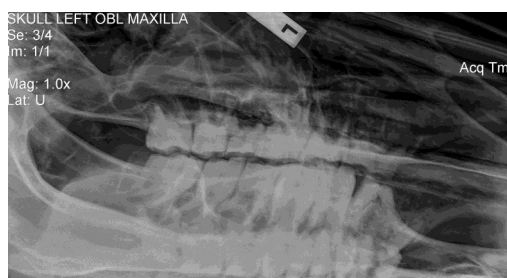Meet Chance. He is a 28yo thoroughbred who had been enjoying the quiet life of retirement. He recently developed a significant purulent nasal discharge from one nostril only. He showed no signs of systemic illness, and his chest sounded clear. A provisional diagnosis of an URTI (upper respiratory tract infection) or sinus infection was made. However, sinus infections often respond poorly to antibiotic therapy alone as there may be reduced drainage or an underlying cause.

Chance was treated with a long course of antibiotics and a dentist had already been booked to do a full oral examination.

Upon follow up several weeks later, although initially the nasal discharge had improved, it had returned and was as significant and profuse as previously. The dentist had also found no abnormalities on oral examination.

It was strongly suspected that the cause the discharge was from a 2° sinus infection. The most common underlying cause of this is a molar cheek tooth, as the roots of these teeth are embedded within and communicate with the maxillary sinus. Other differential diagnosis included; a mass or lesion in the nasal cavity, sinus or ethmoids, a sequestrum, or a guttural pouch lesion.

From a previous consultation, it was known that Chance was very difficult to scope, even when heavily sedated. As such, it was elected that the best diagnostic step was to take xrays of Chance's head and teeth.



Radiographs revealed a significant tooth root lesion of the of the 1st molar (4th cheek tooth) on the upper left side. There was associated damage to the roots of this tooth, the surrounding alveolar bone, and adjacent molars' roots. A physical oral examination confirmed this tooth to be damaged. The tooth and adjacent damaged roots were then successfully removed under sedation.

A month post procedure, Chance had made a full recovery. The nasal discharge had completely resolved and he is back to his happy, relaxed and retired self.